

December 9, 2015

Consultant: Dr. Van Koughnett

Esther Lau PGY2

BOWEL MISCELLANEOUS

“TOP TO BOTTOM”



Objectives

SMALL BOWEL DIVERTICULAR DISEASE

- Etiology and management of jejunal ileal diverticular disease
- Management of complications due to small bowel diverticula including Meckel's diverticulum

COLONIC DIVERTICULAR DISEASE

- Etiology and management of acute colonic diverticular disease
- Complications of colonic diverticular disease

ANAL TUMOURS

- Classification, diagnosis and management of anal margin tumors
- Staging and prognosis of anal margin tumors
- Management of LSIL and HSIL
- Management of Paget's disease and associated tumors
- Diagnosis and management of anal canal tumors
- Staging and prognosis of anal canal tumors
- Role of chemo-radiation in the management of anal canal tumors

We will be using poll everywhere...

- To: **36707**
- Text: **JULIEANNVANK063**



Your poll will show here

1



Install the app from
pollev.com/app

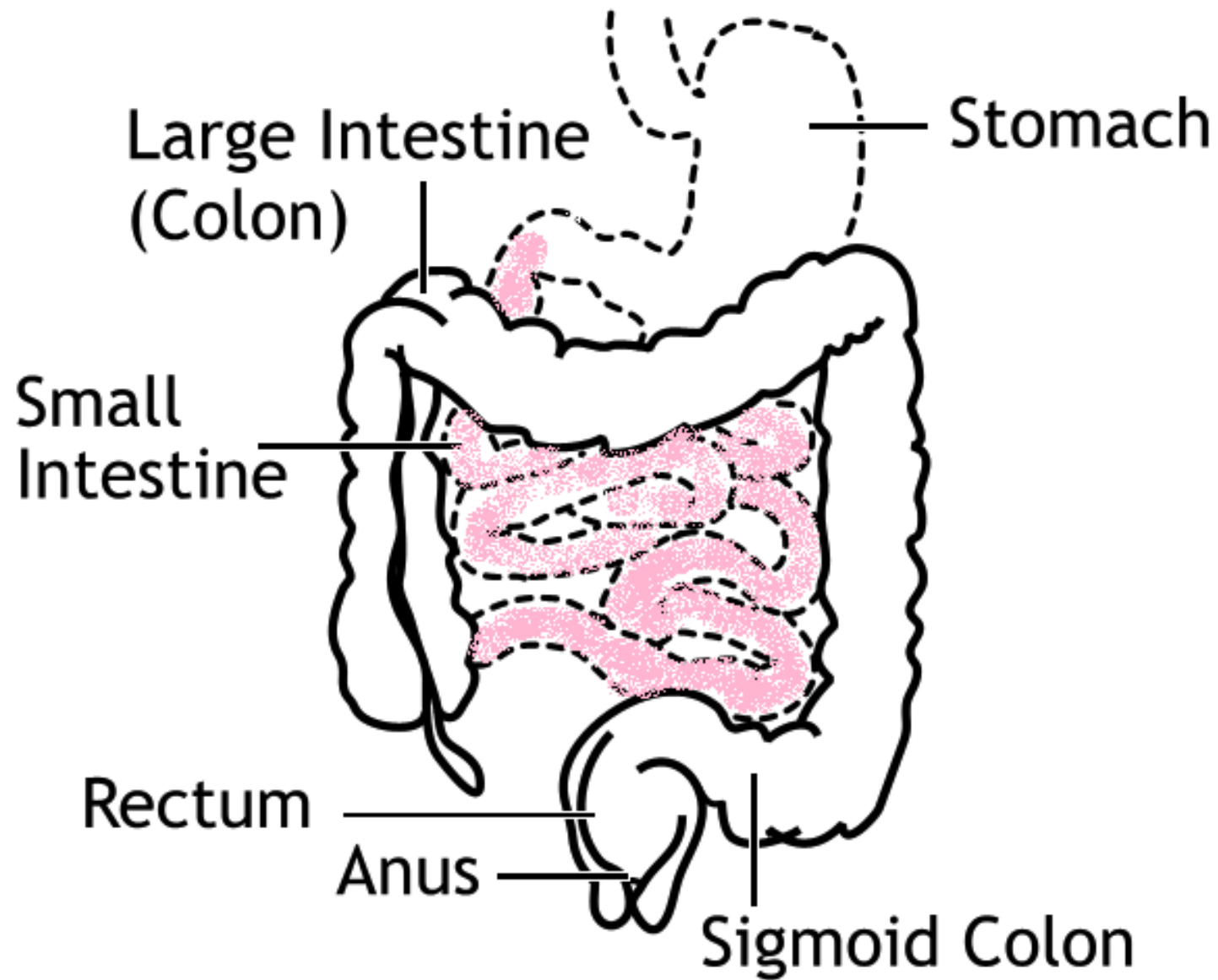
2

Make sure you are in
Slide Show mode

Still not working? Get help at pollev.com/app/help
or

[Open poll in your web browser](#)







Your poll will show here

1



Install the app from
pollev.com/app

2

Make sure you are in
Slide Show mode

Still not working? Get help at pollev.com/app/help
or

[Open poll in your web browser](#)

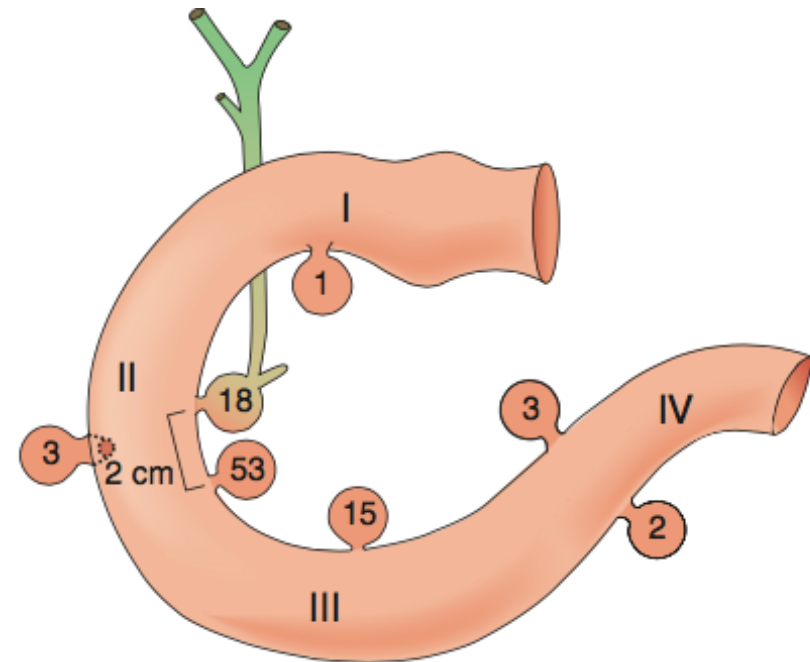


Small Bowel Diverticula

- May present as true or false diverticula
 - **Duodenal diverticula** the most common **acquired** diverticula of the small bowel
 - **Meckel's diverticulum** the most common **true** congenital diverticulum of the small bowel

Duodenal Diverticula

- Relatively common – 2nd most common site for diverticulum formation after the colon
- Up to 20% incidence
- 2/3 – 3/4 found in the periampullary region
- Project from the medial wall of the duodenum



Clinical Presentation

- Majority **asymptomatic**
- Less than 5% will require surgery
- Complications
 - obstruction of the biliary or pancreatic ducts leading to cholangitis and pancreatitis
 - hemorrhage
 - perforation
 - blind loop syndrome



Your poll will show here

1


Install the app from
pollev.com/app

2

Make sure you are in
Slide Show mode

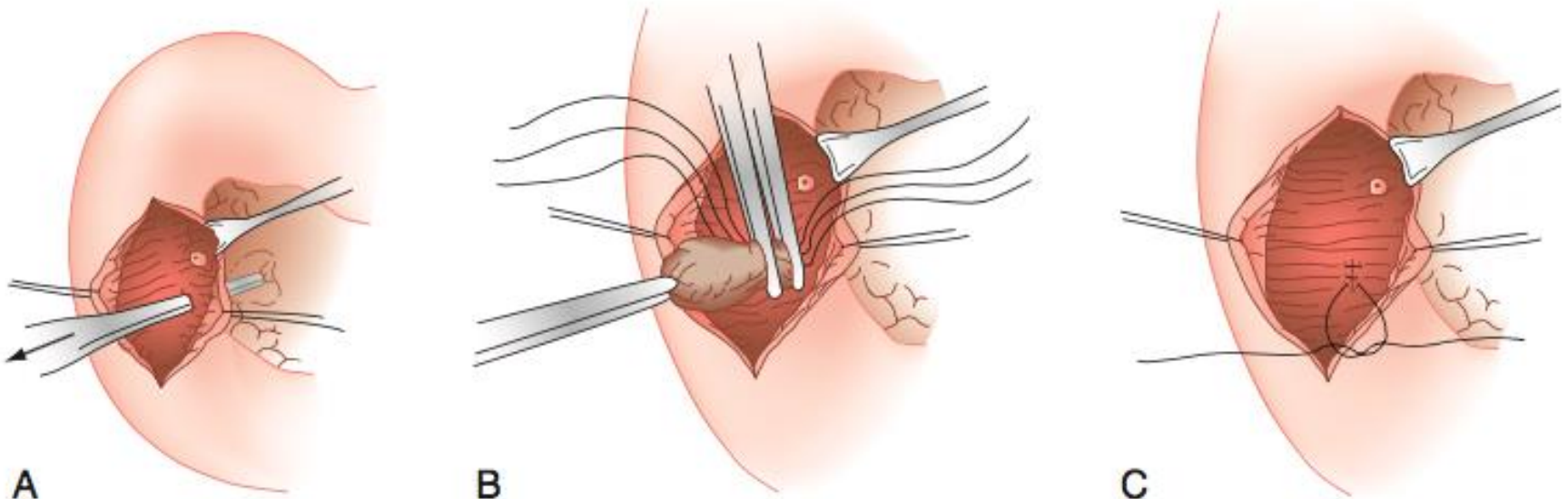
Still not working? Get help at pollev.com/app/help
or

[Open poll in your web browser](#)



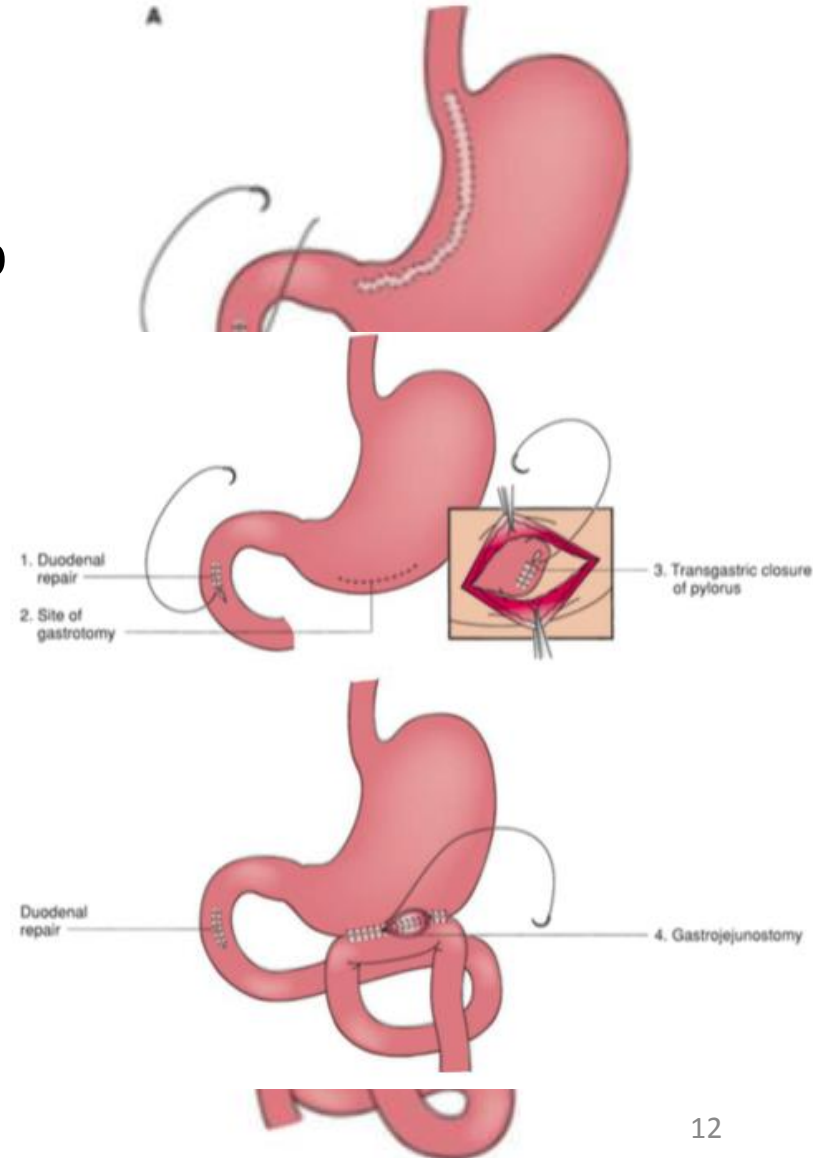
Treatment

- If symptomatic, most common is **diverticulectomy**
 - wide Kocher maneuver to expose duodenum
 - diverticulum is excised and duodenotomy closed



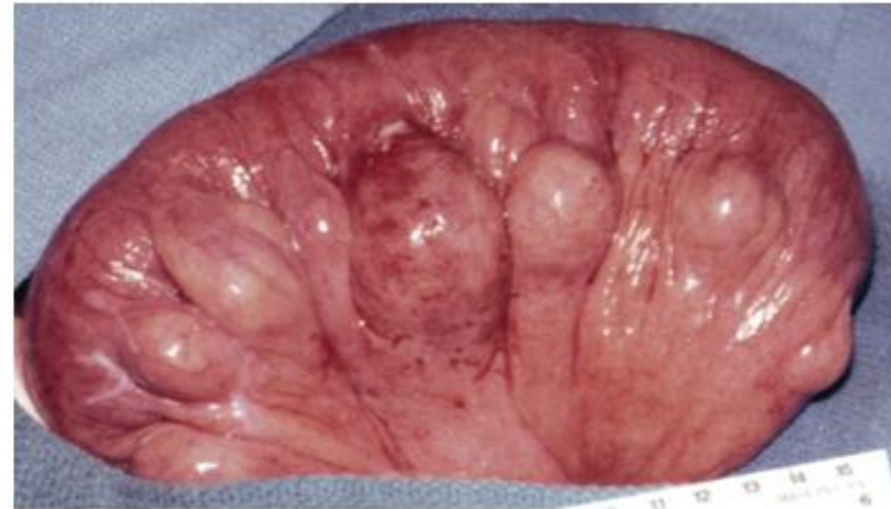Treatment

- If **perforated**, diverticulum should be excised and duodenum closed with serosal patch from jejunal loop
- May require diversion with gastrojejunostomy or duodenojejunostomy
- If diverticulum is posterior and perforates into the pancreas, operative repair may be dangerous
 - wide drainage with pyloric exclusion



Jejunioileal Diverticulosis

- Pseudo-diverticula
 - wall includes mucosal and submucosal layers
- Likely consequence of small bowel motility disorder
- 40-50% have concurrent pseudodiverticula in the colon and duodenum





Your poll will show here

1



Install the app from
pollev.com/app

2

Make sure you are in
Slide Show mode

Still not working? Get help at pollev.com/app/help
or

[Open poll in your web browser](#)

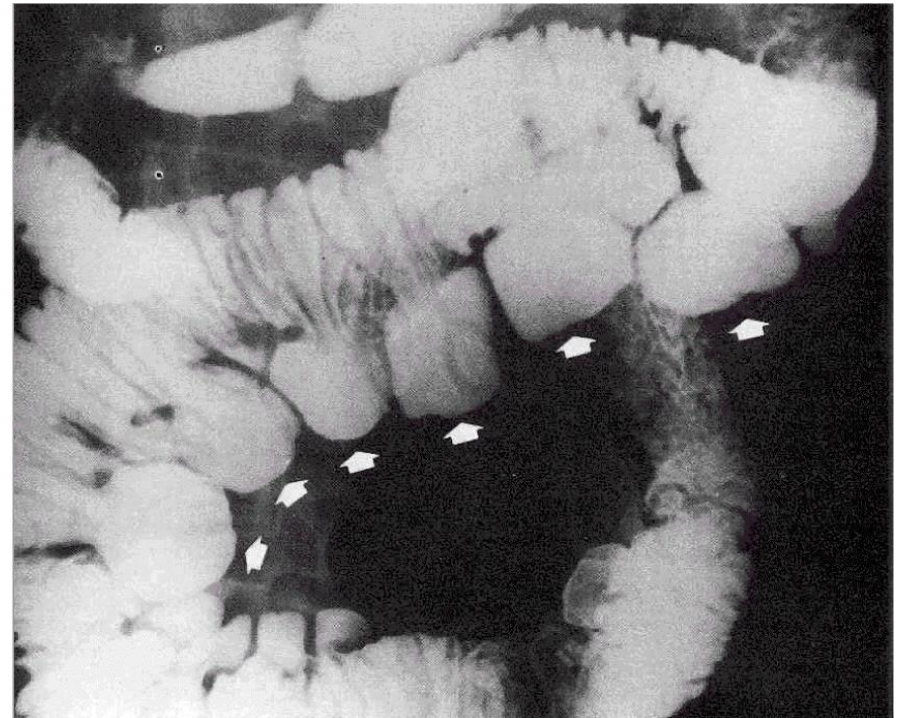


Jejunioileal Diverticulosis

- Found at the mesenteric border

Distribution:

- 80% jejunum
- 15% ileum
- 5% throughout small bowel
- Rare (0.1 – 2.3%)
- Usually in 7th decade of life



Clinical Presentation

- Majority (50-60%) asymptomatic
- 20-40% nonspecific abdominal complaints
 - pain, postprandial bloating, diarrhea, malabsorption, vitamin B12 deficiency
- 10-15% acute complications
 - bleeding, diverticulitis, perforation

Management

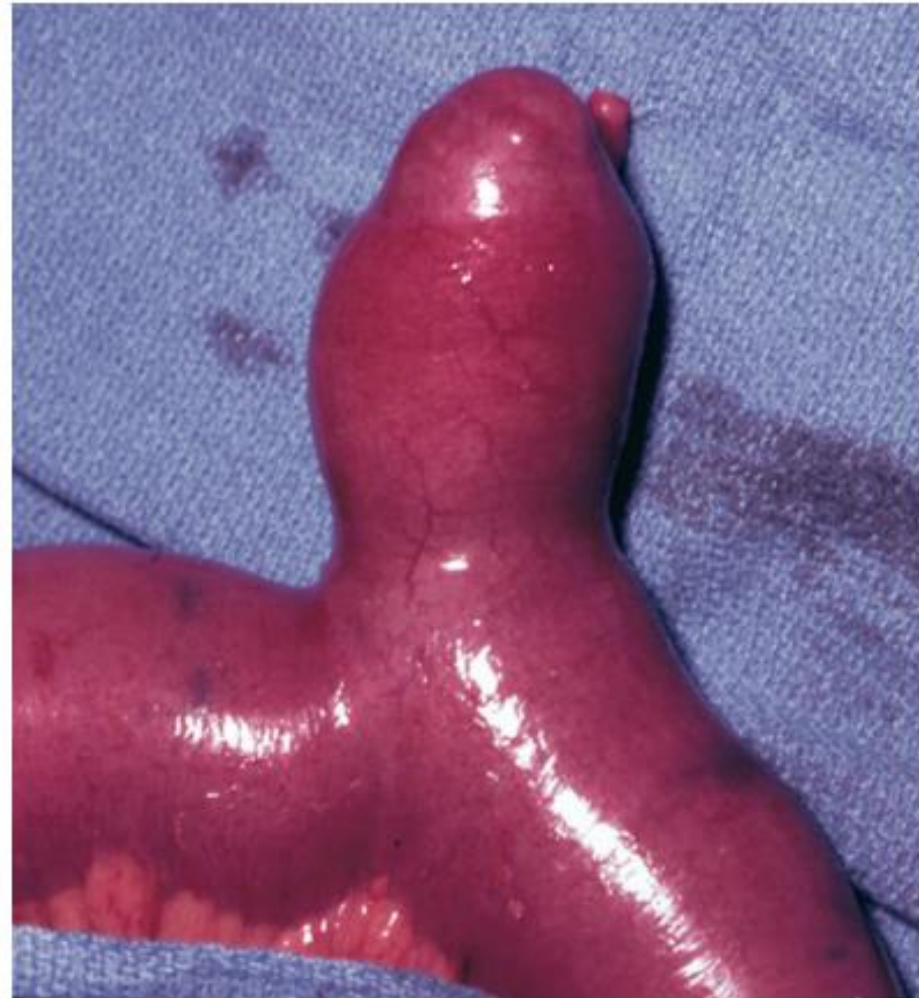- Asymptomatic – no indication for resection
- Chronic symptoms
 - high-protein, low-residue diet
 - vitamin B12 supplementation
 - intermittent broad-spectrum antibiotic
- Acute complications
 - resection with anastomosis

Surgical Management

- **Obstruction** caused by enteroliths that form in a jejunal diverticulum
 - enterotomy and removal of the enterolith
 - if obstruction at the level of diverticulum, bowel resection necessary
- **Perforation** of a jejunoileal diverticulum
 - resection with anastomosis

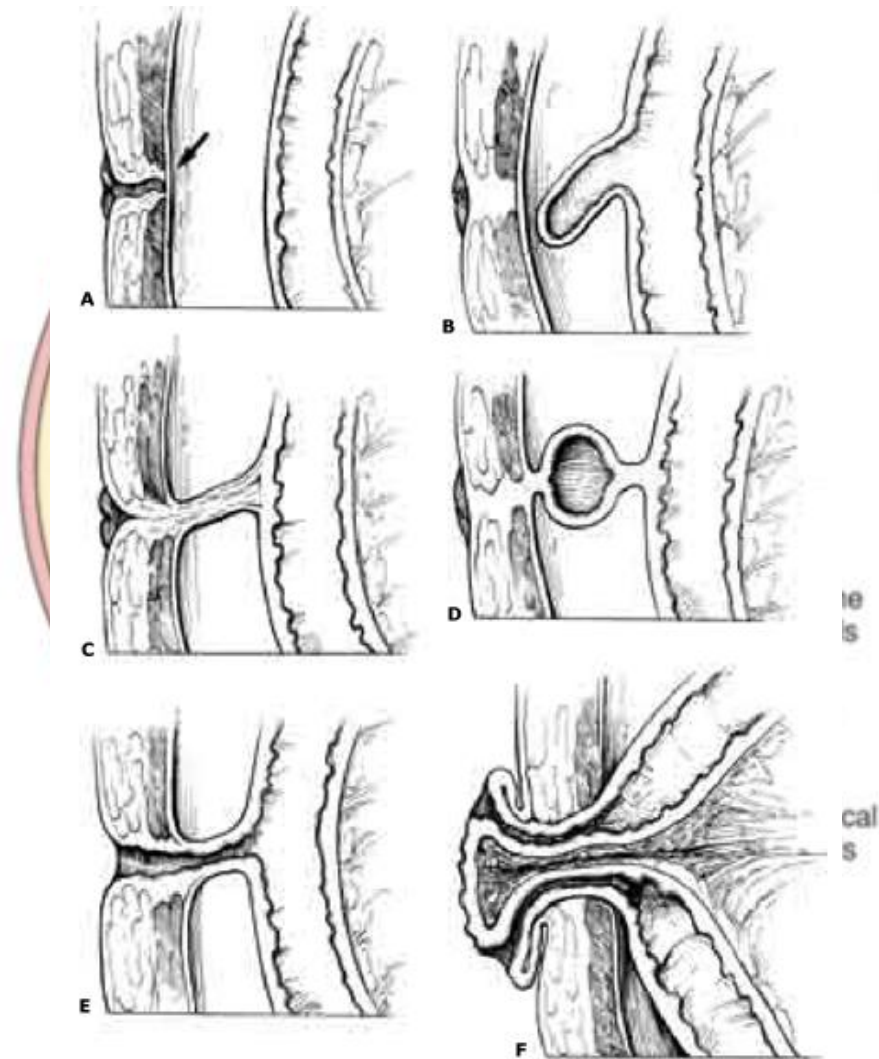
Meckel's Diverticulum

- True diverticulum
- Results from incomplete closure of yolk stalk
- Arise from the antimesenteric surface of the middle-to-distal ileum



Embryology

- The embryonic yolk stalk connects the yolk sac and the developing midgut
- Weeks 5-7 of gestation:
 - yolk stalk involutes
- Failure to involute → spectrum of clinical malformations



Rule of 2's

- 2 feet from ileocecal valve
- 2% incidence
- 2:1 male:female predominance
- half of those with symptoms < age 2
- 2 types of heterotopic mucosa (gastric, pancreatic, duodenal)



Your poll will show here

1



Install the app from
pollev.com/app

2

Make sure you are in
Slide Show mode

Still not working? Get help at pollev.com/app/help
or

[Open poll in your web browser](#)



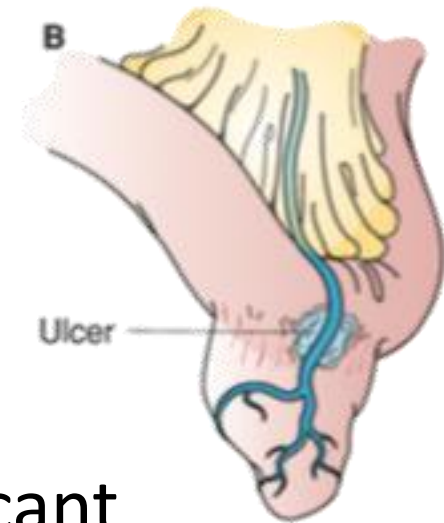
Clinical Presentation

Clinical Presentation	Frequency (%)
Hemorrhage	30-35
Small bowel obstruction	30-35
Diverticulitis	20-25
Umbilical fistula	10
Other	Uncommon

Lifetime risk of a complication from a Meckel diverticulum is about 4%

Hemorrhage

- Results from peptic ulceration of the adjacent ileal mucosa
- Painless, episodic hemorrhage that is typically bright red to maroon
- Generally not hemodynamically significant
- Incidence greatest in the first decade of life





Your poll will show here

1



Install the app from
pollev.com/app

2

Make sure you are in
Slide Show mode

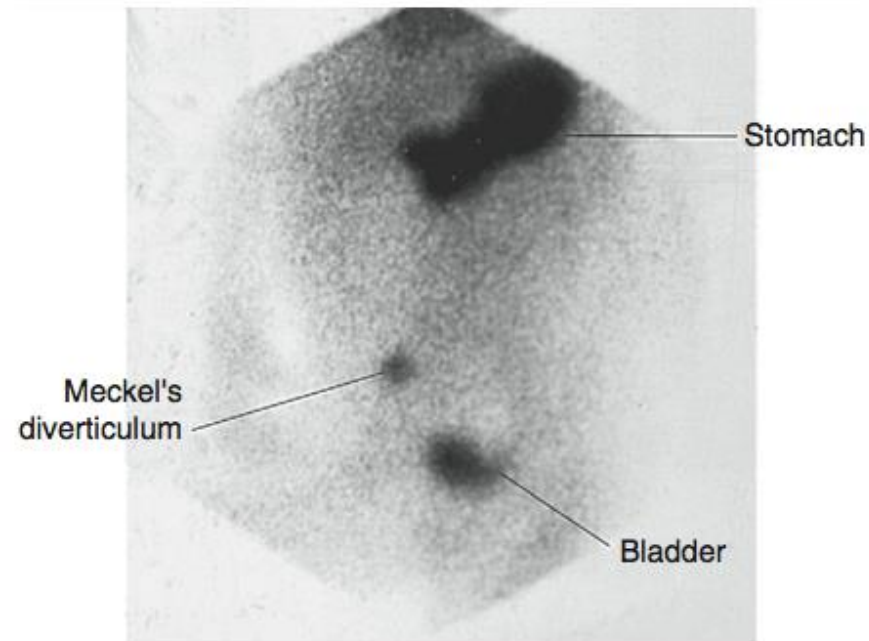
Still not working? Get help at pollev.com/app/help
or

[Open poll in your web browser](#)



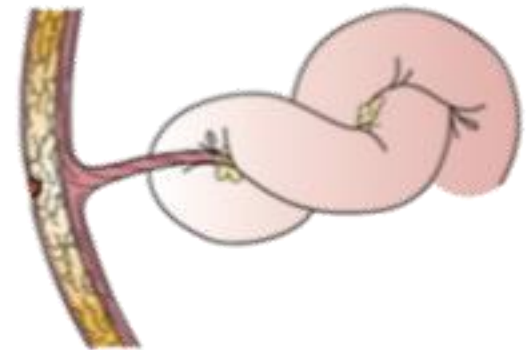
Management

- **^{99m}Tc -pertechnetate radioisotope scan**
 - nuclear medicine study in which ^{99m}Tc technetium pertechnetate binds to gastric mucosa
 - perform in patients who are hemodynamically stable and high suspicion for Meckel's diverticulum
 - more applicable in pediatric population
- **Segmental resection** required as bleeding site is usually in the ileum adjacent to the diverticulum



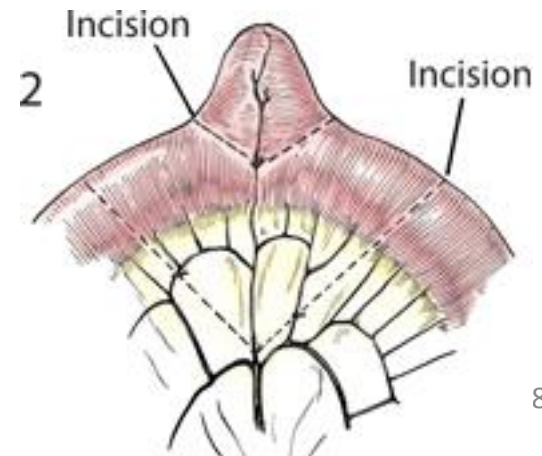
Obstruction

- **Intussusception** where broad-based diverticulum invaginates and then is carried forward by peristalsis
- **Volvulus** around an abnormal attachment between the bowel and the abdominal wall



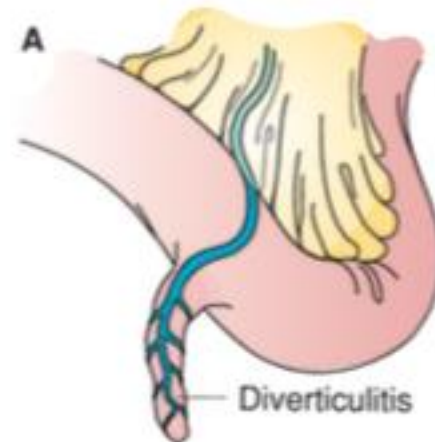
Management

- NG decompression
- Operative exploration and possible segmental resection
 - Viability of the bowel wall delineates the extent of excision
 - Broad-based diverticulum should have segmental resection to avoid ileal stenosis



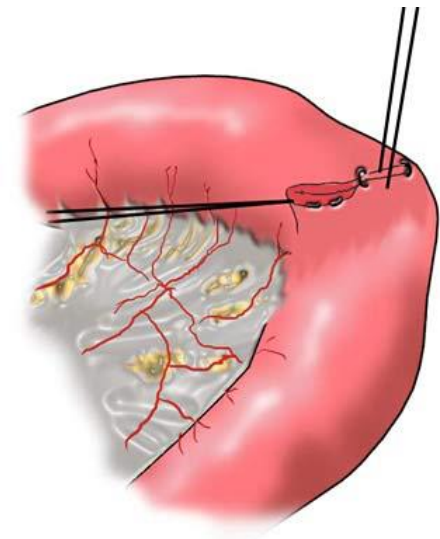
Diverticulitis

- Intraluminal obstruction at the base of Meckel diverticulum
- Signs and symptoms virtually indistinguishable from appendicitis



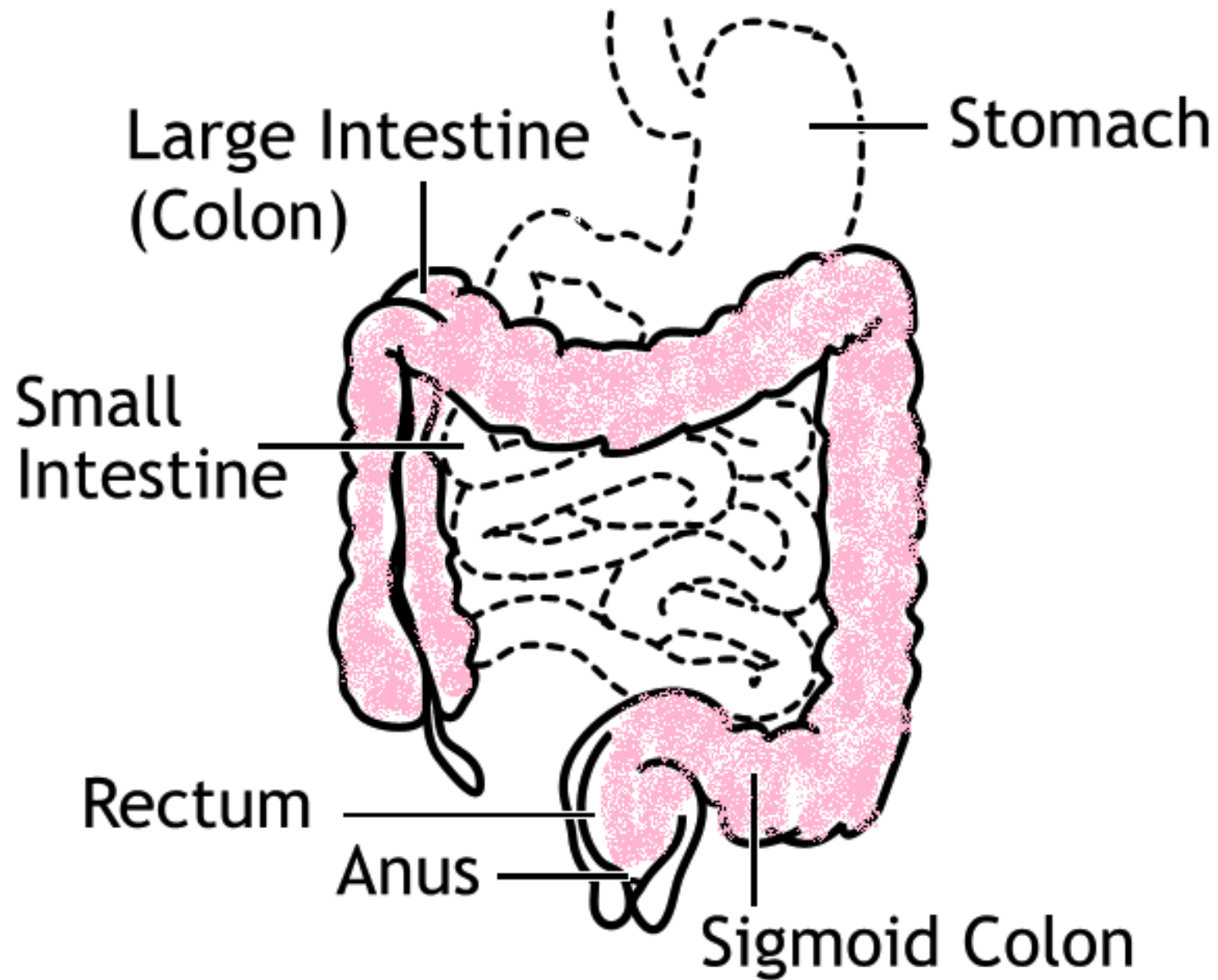
Management

- Diverticulectomy
 - hand-sewn technique or stapling across the base of the diverticulum in a diagonal or transverse line to minimize the risk for subsequent stenosis
- If during exploration for suspected appendicitis, the appendix is discovered to be normal, examine the distal ileum for diverticulitis



Incidentally-discovered Meckel's diverticulum

- Controversial – depends on reason for operative exploration, age, potential for future symptoms
 - Clearly indicated if heterotopic gastric mucosa present
 - Abnormal omphalomesenteric bands to the abdominal wall should be excised



Colonic Diverticulosis

- Pseudo-diverticula
- Most commonly in sigmoid
 - 95% of patients
 - 30-60% isolated to the sigmoid colon
 - 7-10% total colonic involvement (rectum spared)
- Rare in non-industrialized, less affluent societies

Age	≤ 25 y	≤ 45 y	> 60 y	> 80 y
Incidence	1-2%	33%	40%	60%

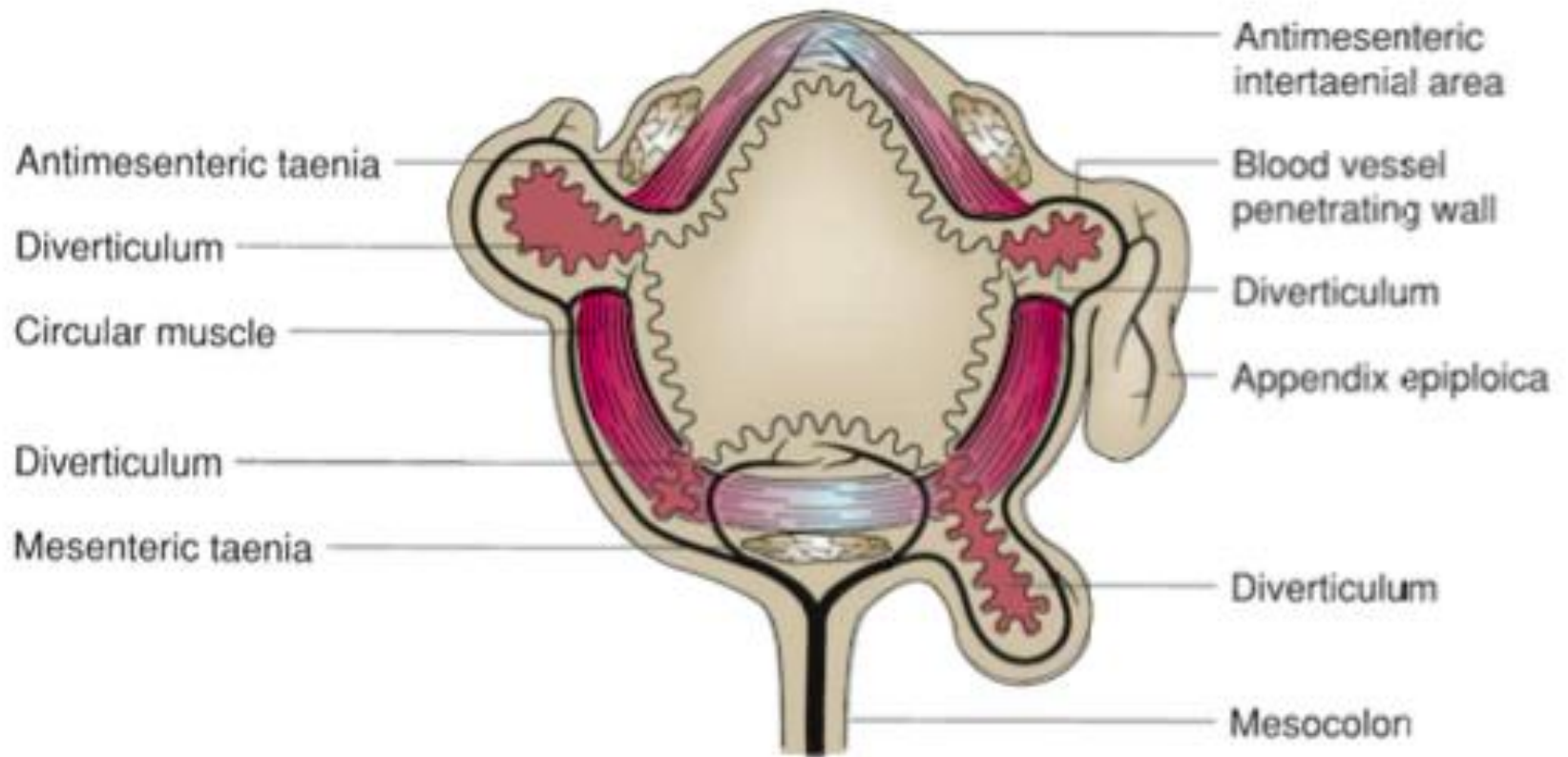
Etiology

- Lack of dietary fiber
- Slow colonic transit
- Colonic structural abnormalities
- Age-related changes

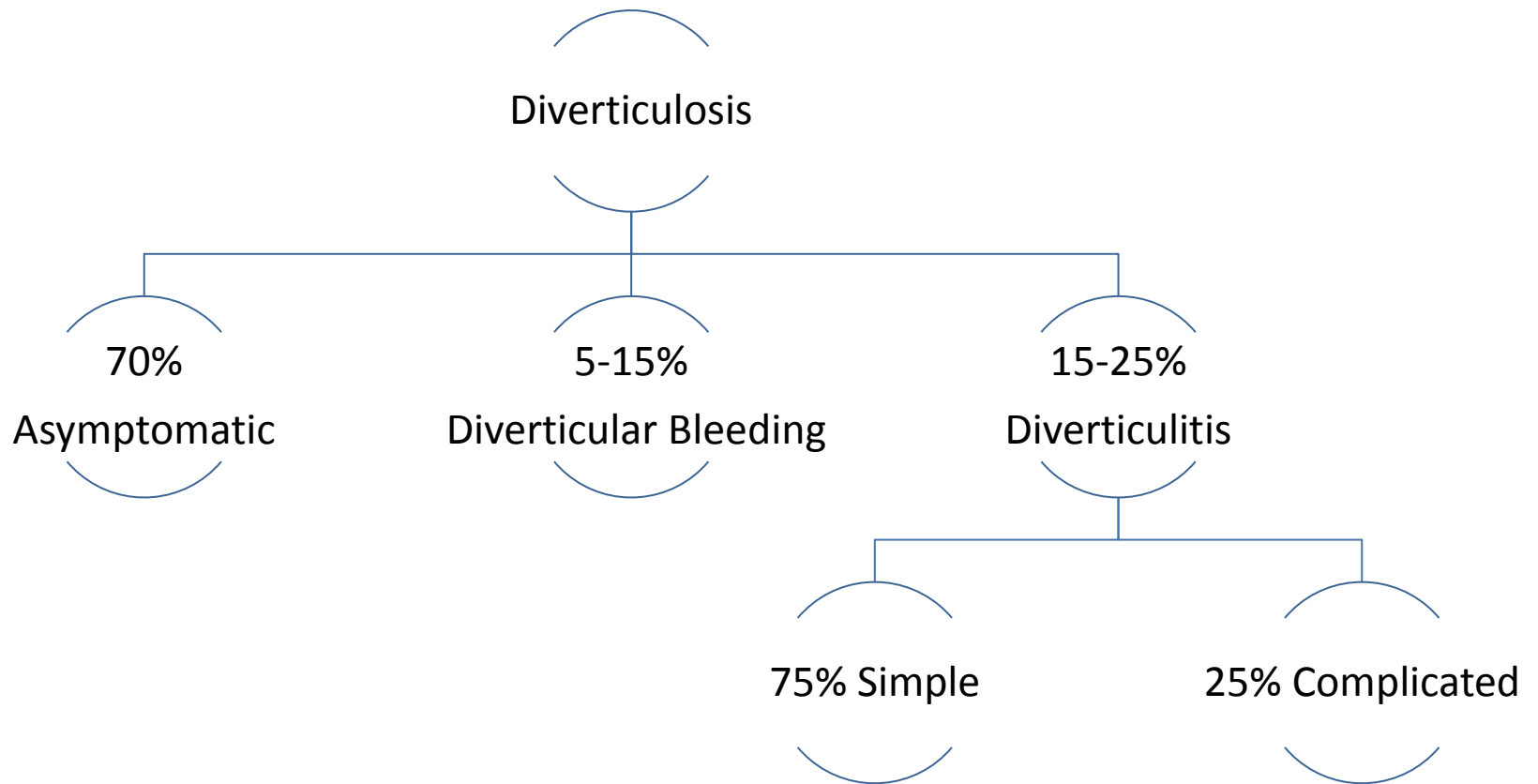
Diet

- Decreased dietary fiber most consistently associated with high incidence of diverticulosis (Painter and Burkitt 1971)
- Improvement of diverticular disease symptoms in patients who increased dietary fiber
- Rising incidence among previously low-risk populations with changes to a Western-style diet
- Nuts and seeds *not* associated with diverticular complications (Strate JAMA 2008)

Structural/Anatomical Factor



Natural History of Diverticulosis





Your poll will show here

1



Install the app from
pollev.com/app

2

Make sure you are in
Slide Show mode

Still not working? Get help at pollev.com/app/help
or

[Open poll in your web browser](#)



Complications

- **Abscess**
 - 17% of patients hospitalized for diverticulitis
- **Obstruction**
 - pericolonic inflammation or compression from a diverticular abscess
 - stricture due to chronic diverticular inflammation
 - SBO from pericolonic inflammation or ileus
- **Fistula**
 - fistula between the colon and adjacent viscera (bladder, vagina)
- **Perforation**
 - although only 1-2% of patients with acute diverticulitis have a perforation with purulent or fecal peritonitis, mortality rates approach 20%

Clinical Presentation

- LLQ abdominal pain
 - may be RLQ/suprapubic if redundant sigmoid or R-sided diverticulitis in Asian populations
- Nausea and vomiting
- Hemodynamic instability associated with perforation and peritonitis
- 20% palpable tender mass
- Change in bowel habits
 - 50% constipation
 - 25-35% diarrhea
- 10-15% urinary urgency/frequency/dysuria

Ddx

- Colorectal cancer
- Acute appendicitis
- Perforated peptic ulcer
- Acute ischemic colitis
- Flare of Crohn's disease or ulcerative colitis



Your poll will show here

1


Install the app from
pollev.com/app

2

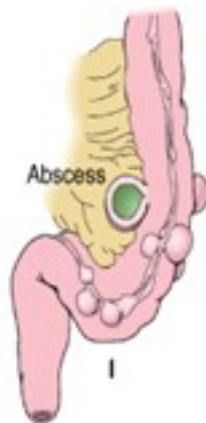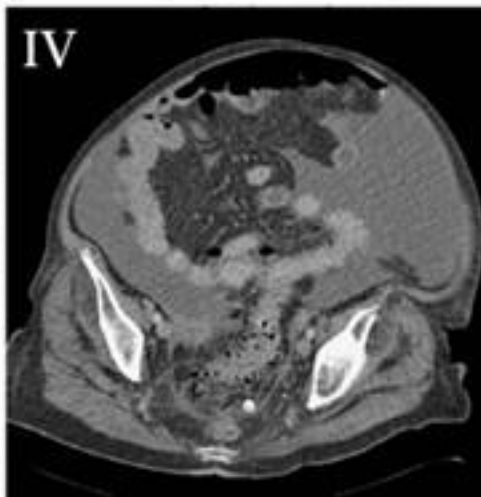
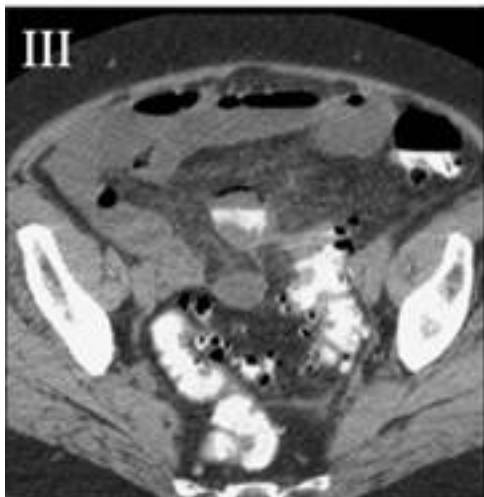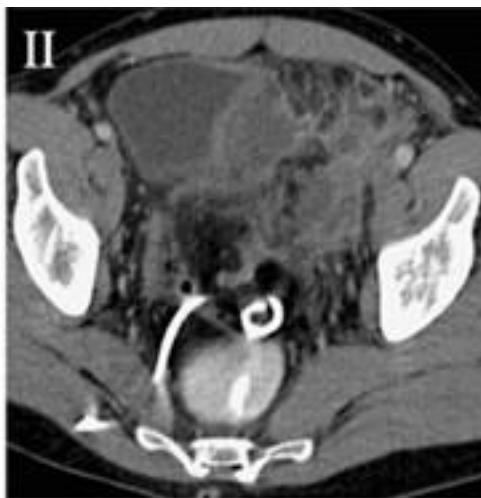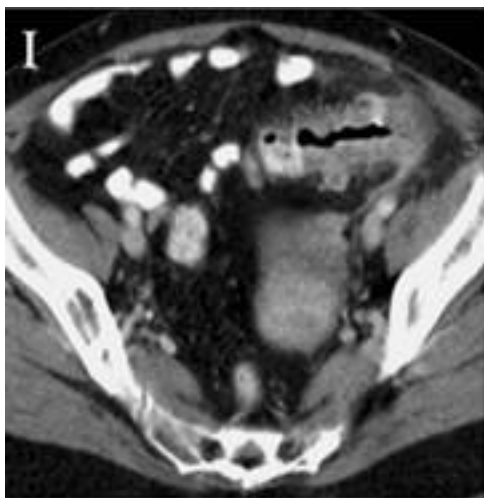
Make sure you are in
Slide Show mode

Still not working? Get help at pollev.com/app/help
or

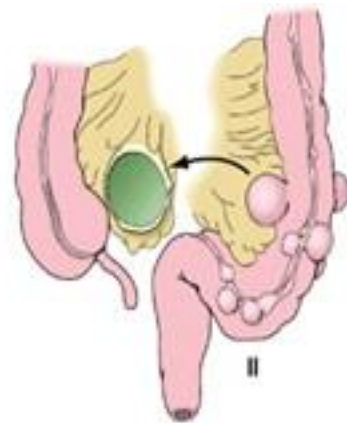[Open poll in your web browser](#)



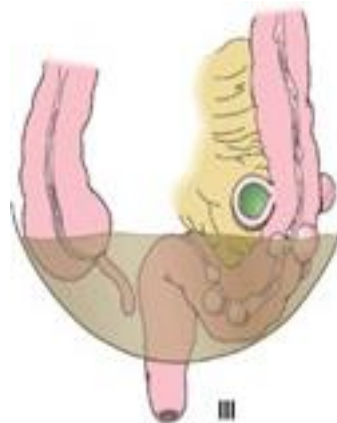Hinchey's Classification



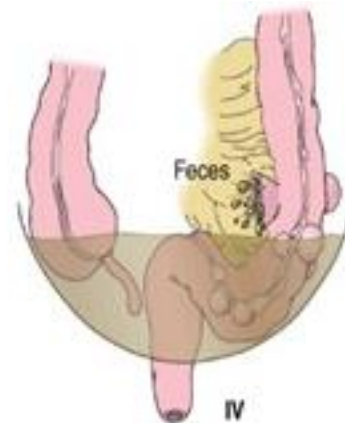Pericolic or
mesenteric
abscess



Walled-off pelvic
abscess



Generalized purulent
peritonitis



Generalized fecal
peritonitis

Treatment

Hinchey Classification		
I	Pericolic or mesenteric abscess	Antibiotics and bowel rest <ul style="list-style-type: none">• consider outpatient management if no systemic symptoms• if abscess >2cm, percutaneous drainage• if fail medical, operative management
II	Walled-off pelvic abscess	Percutaneous drainage, antibiotics, and bowel rest <ul style="list-style-type: none">• if fail medical, operative management
III	Generalized purulent peritonitis	Resuscitation and urgent operation <ul style="list-style-type: none">• resect, consider primary anastomosis
IV	Generalized fecal peritonitis	Resuscitation and urgent operation <ul style="list-style-type: none">• resect, consider staged procedure

Following Medical Management

- Colonoscopy 6-8 weeks following resolution
 - if first episode or recent colonoscopy has not been performed
- High-fibre diet
- Discussion regarding elective surgery



Your poll will show here

1



Install the app from
pollev.com/app

2

Make sure you are in
Slide Show mode

Still not working? Get help at pollev.com/app/help
or

[Open poll in your web browser](#)



Elective Surgery after *Uncomplicated* Acute Diverticulitis

- Historically, after 1st episode, approximately 1/3 will develop 2nd attack and of those, another 1/3 will have a 3rd attack
- More recent studies:
 - lower recurrence ranges of 13-23%
 - low rates of subsequent complicated disease or need for surgery (<6%)
 - 18 patients would need to undergo elective colectomy to prevent 1 emergency surgery for recurrent diverticulitis
- Most patients who present with complicated diverticulitis do so at the time of their first attack
- **Decision to recommend elective sigmoid colectomy after recovery from uncomplicated acute diverticulitis should be individualized**

Special Considerations

- **Immunosuppressed patients**
 - associated with an increased incidence of perforated diverticulitis
 - surgical resection after a single attack should be considered
- **Young patients**
 - traditionally patients < age 50 recommended resection after single episode
 - no data to support this recommendation

Elective Surgery after *Complicated* Acute Diverticulitis

- Complicated diverticulitis includes those episodes associated with free perforation, large abscess, fistula, obstruction, or stricture
- Elective colectomy recommended as up to 40% recurrence rate

Emergent Operative Considerations

- Urgent sigmoid colectomy is required for patients with diffuse peritonitis or for those in whom non-operative management fails
- To restore bowel continuity or not?
 - colorectal anastomosis +/- diverting colostomy or ileostomy versus constructing an end-colostomy
 - literature comparing the 2 is retrospective and suffers from selection bias

A Multicenter Randomized Clinical Trial of Primary Anastomosis or Hartmann's Procedure for Perforated Left Colonic Diverticulitis With Purulent or Fecal Peritonitis

Christian Eugen Oberkofler, MD, Andreas Rickenbacher, MD,* Dimitri Aristotle Raptis, MD, MSc,* Kuno Lehmann, MD,* Peter Villiger, MD,† Christian Buchli, MD,† Felix Grieder, MD,‡ Hans Gelpke, MD,‡ Marco Decurtins, MD,‡ Adrien A. Tempia-Caliera, MD,§ Nicolas Demartines, MD,§ Dieter Hahnloser, MD,§ Pierre-Alain Clavien, MD, PhD,* and Stefan Breitenstein, MD**

Ann. Surg 2012

- RCT
- 62 patients with acute left-sided colonic perforation (Hinchey III and IV) from 4 centers
- Randomized to Hartmann's procedure versus primary anastomosis with diverting ileostomy
- Primary end point: overall complication rate
- Study stopped early as interim analysis demonstrated Hartmann reversal had significantly more serious complications (20% versus 0%) compared with ileostomy reversal
- **Decision to create an anastomosis in setting of peritonitis should be individualized**

Technical Considerations

- Inflammation distorts the anatomic planes
- Medial- to-lateral approach may sometimes be needed to mobilize the sigmoid
- Though typically not needed, placement of ureteral stents may be helpful
- Proximal resection line should be at soft, pliable bowel
- Distal resection line must be at the top of the rectum
- Splenic flexure should almost always be mobilized to tension-free colorectal anastomosis
- Anastomosis free from diverticula

Fistula

- Usually obviates the need for emergency operation
- Pre-operative colonoscopy to exclude colon cancer or Crohn's disease
- Single-stage operation
- No repair of the bladder is needed unless visibly patent opening
 - urinary drainage catheter 7 to 10 days after surgery
- Fistula tract openings to the vaginal cuff do not require closure
 - may use omentum to separate anastomosis from opening

Giant Colonic Diverticulum

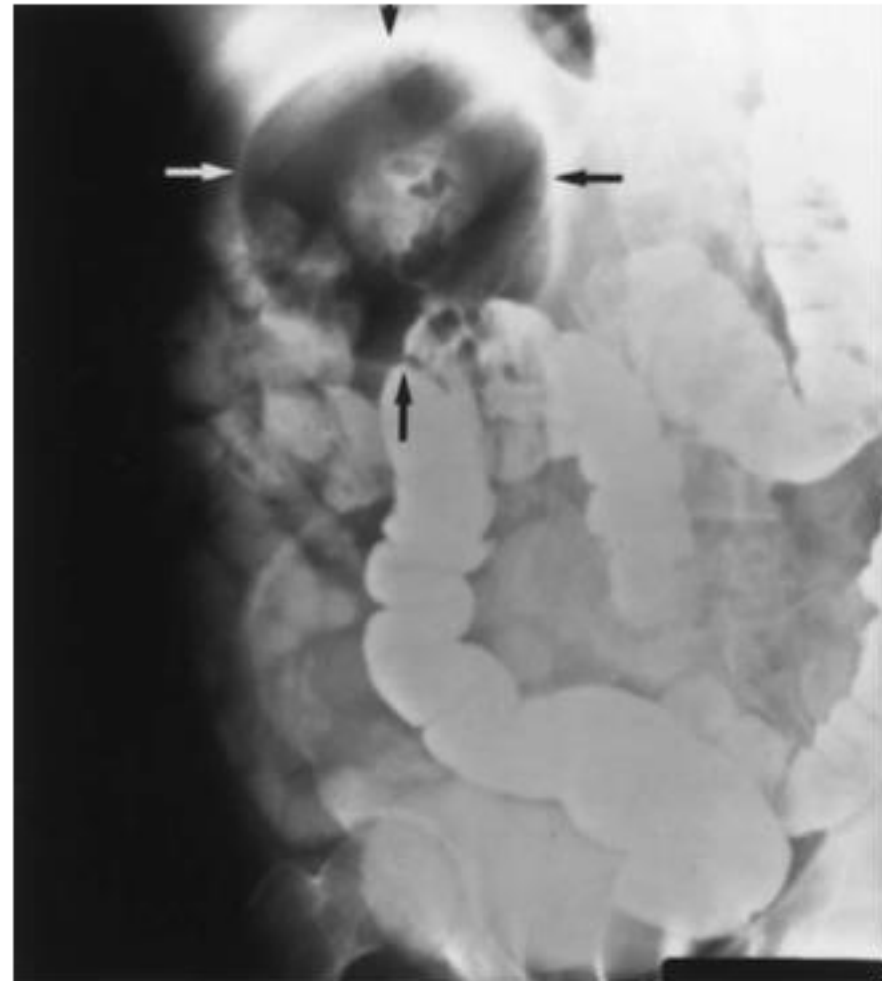
- Colonic pseudodiverticulum >4cm
- Associated with sigmoid diverticular disease
- Arise from the antimesenteric border of the sigmoid
- Etiology unclear
- Theory: unidirectional flap-valve mechanism at the base of the diverticulum that traps bowel gas and debris

Clinical Presentation

- Vague abdominal discomfort
- Soft, mobile abdominal mass
- Complications:
 - perforation
 - obstruction
 - volvulus

Diagnosis

- AXR – large, solitary gas-filled cavity





Your poll will show here

1


Install the app from
pollev.com/app

2

Make sure you are in
Slide Show mode

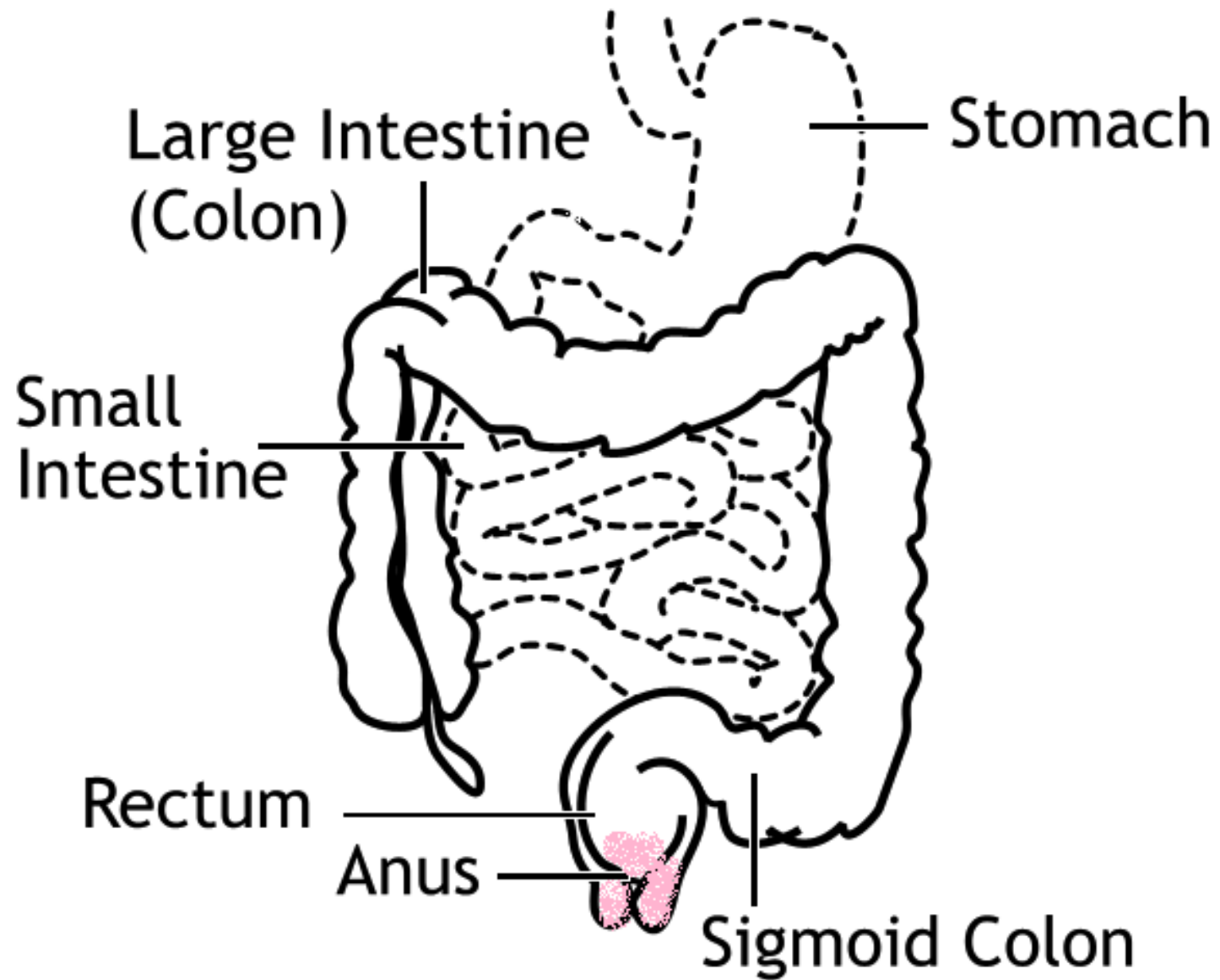
Still not working? Get help at pollev.com/app/help
or

[Open poll in your web browser](#)



Management

- Surgical resection of involved colon
 - elective, single-staged
- If perforated, operative decision parallels common diverticulitis





Your poll will show here

1



Install the app from
pollev.com/app

2

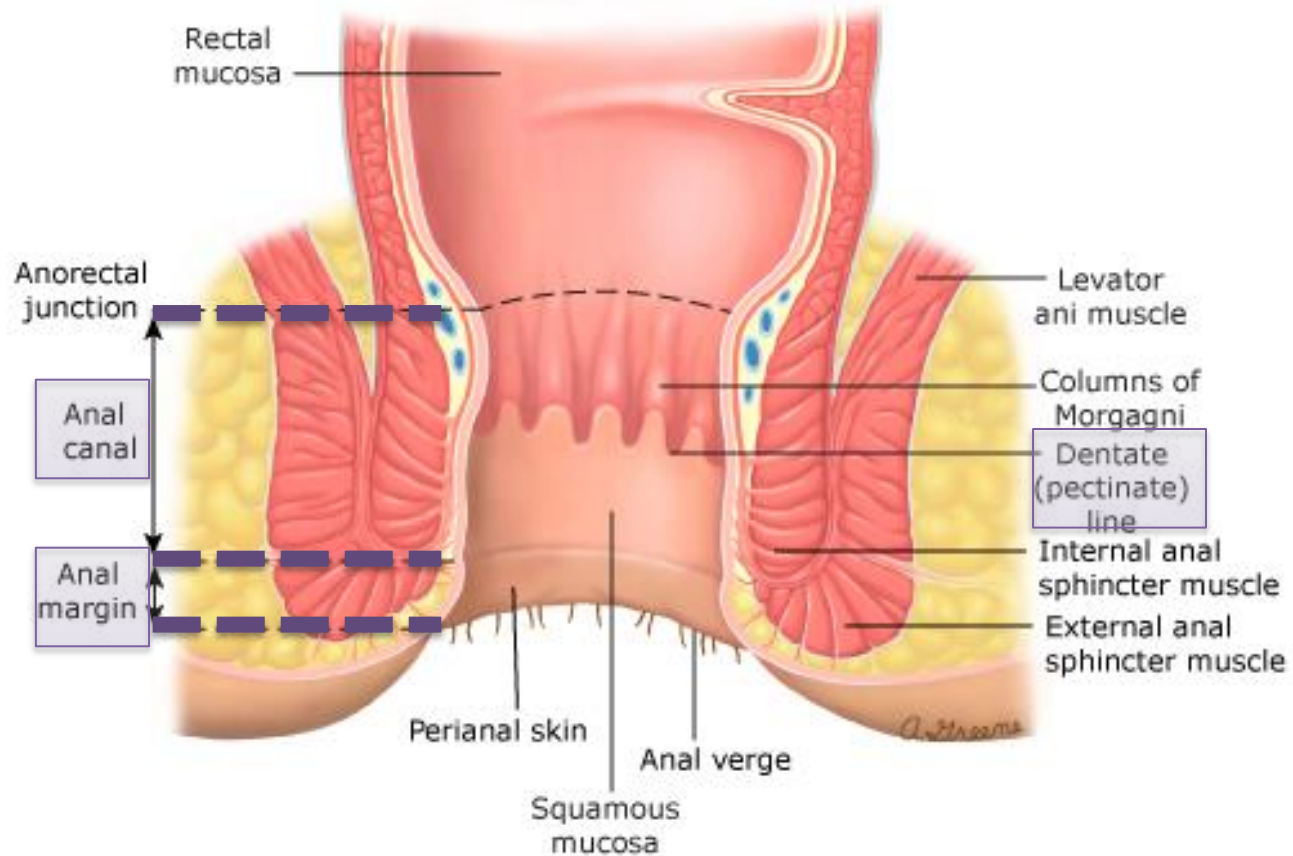
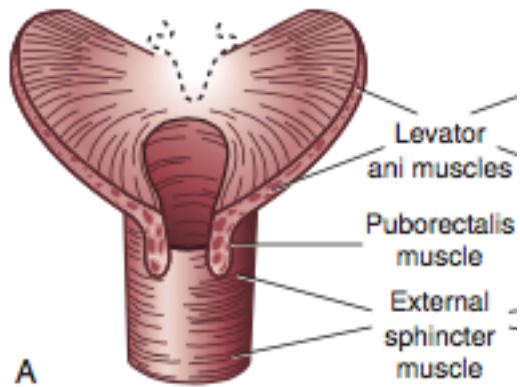
Make sure you are in
Slide Show mode

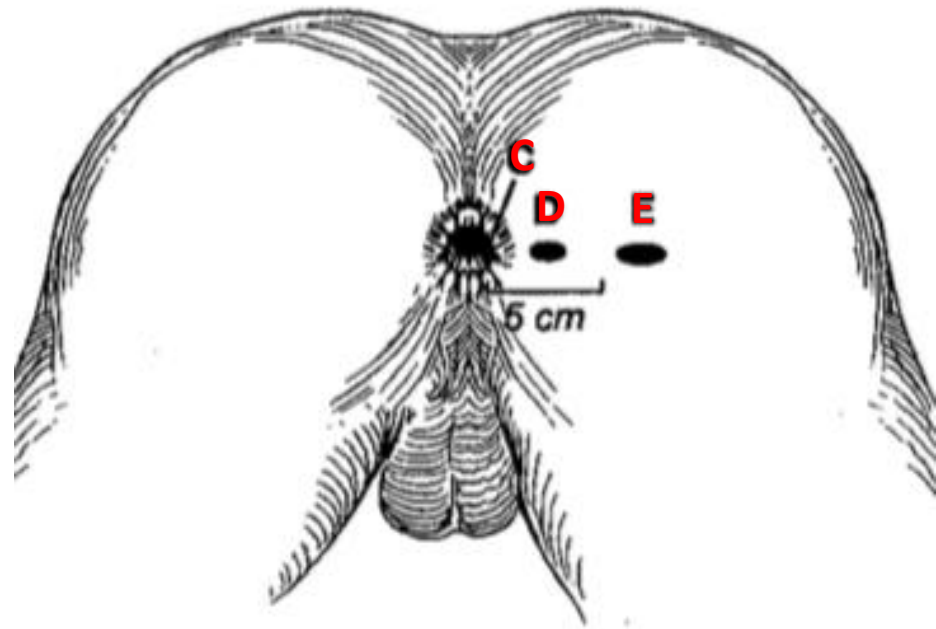
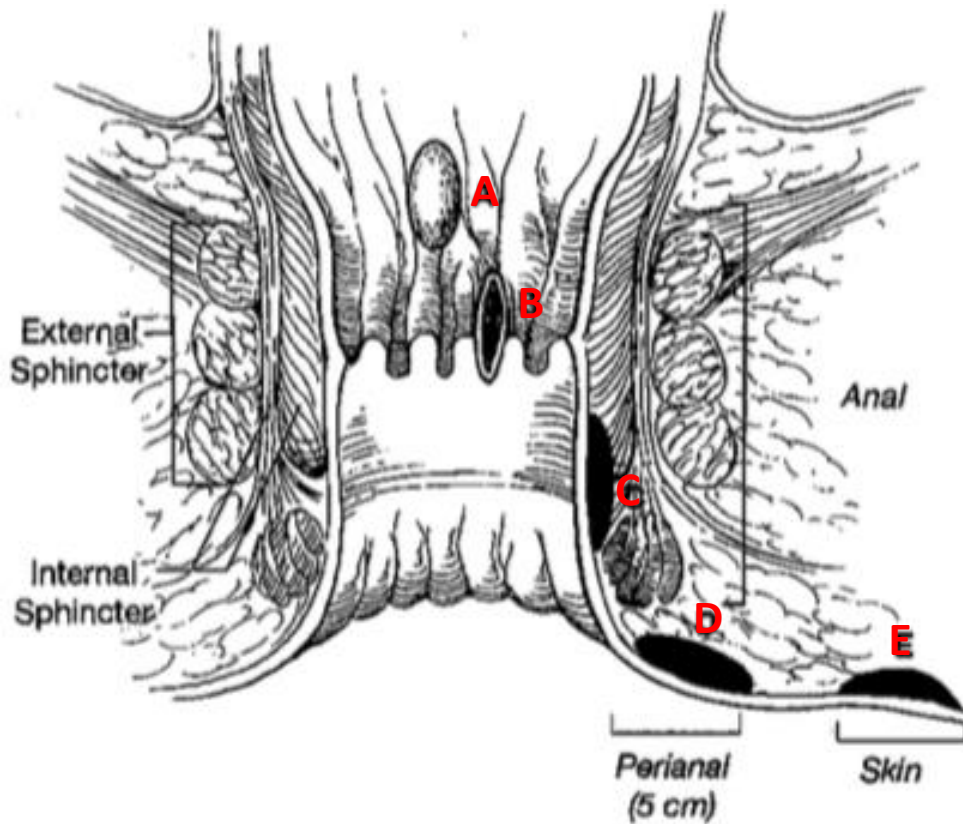
Still not working? Get help at pollev.com/app/help
or

[Open poll in your web browser](#)



Anus



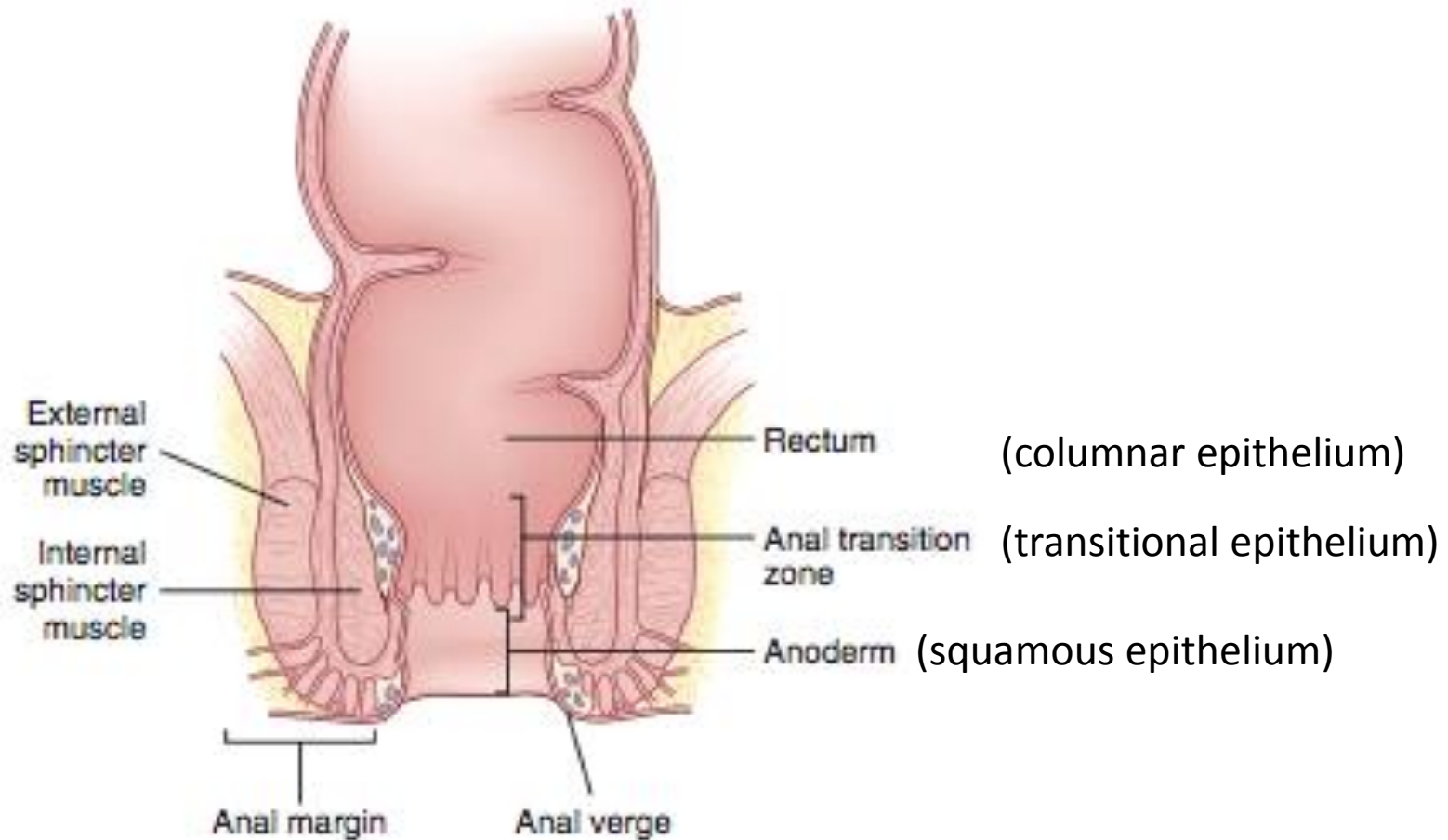


Tumours A, B, C – anal canal cancer

Tumour D – perianal cancer

Tumour E – skin cancer

Anal Canal Lining



Anal Cancer

Anal Canal Cancers

- Tumors arising from any of the three types of mucosa
 - **Squamous cell carcinoma**
 - Adenocarcinoma
 - Melanoma
 - GIST

Anal Margin Cancers

(aka Perianal Cancers)

- Essentially skin malignancy arising between the distal end of the anal canal and a 5-cm margin surrounding the anal verge
 - **Squamous cell carcinoma**
 - Paget's disease
 - Basal cell carcinoma
 - Verrucous carcinoma

Anal Canal Cancer

- Pain and bleeding are common
- Up to 20% of patients may be asymptomatic
- Groin pain if lymphatic spread to inguinal/femoral nodes
- Diagnosis often delayed
- Liver and lungs most common sites of distant metastases



Your poll will show here

1


Install the app from
pollev.com/app

2

Make sure you are in
Slide Show mode

Still not working? Get help at pollev.com/app/help
or

[Open poll in your web browser](#)

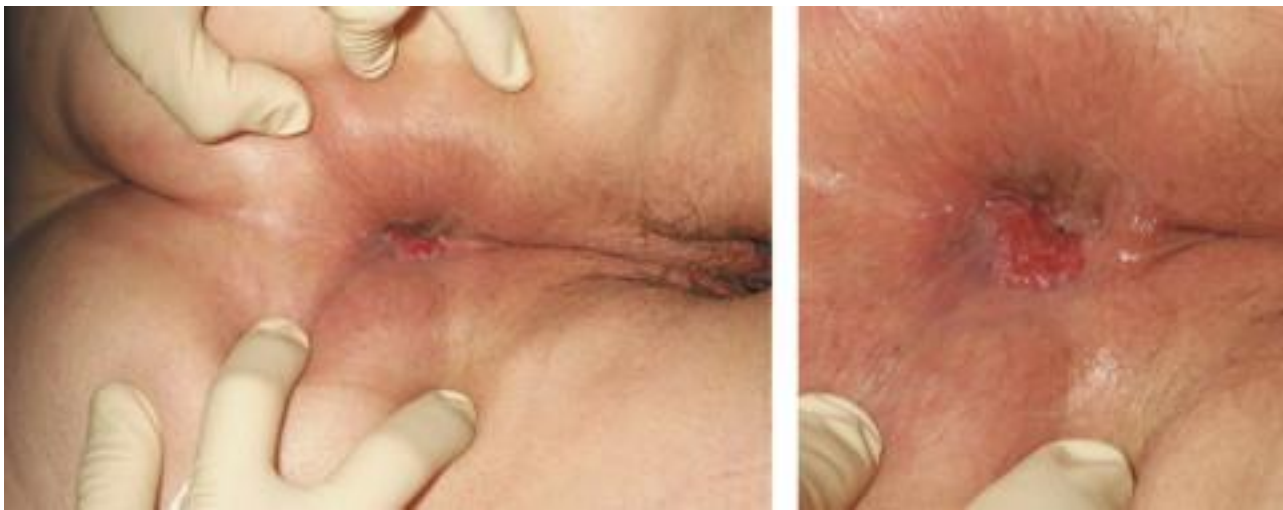

Risk Factors

- Infection with HPV
 - serotypes **16, 18**, 31, 33, 35
- Hx other HPV-related genital malignancies
- HIV seropositivity
- Previous sexually acquired diseases
- Cigarette smoking
- Anoreceptive intercourse
- Multiple sexual partners
- Hx solid organ transplant
- Other forms of immunosuppression

Physical Exam

- Anorectal examination
 - evaluate for fixation and the presence of sphincter invasion
- Inguinal and femoral node examination
 - lymphadenopathy needs biopsy
- Anoscopy or proctoscopy with biopsy
 - determine size and location of lesion
 - confirm diagnosis



Investigations

- Colonoscopy
 - colorectal neoplasms demonstrated in up to 15% of patients with anal cancer
- CT chest/abdo/pelvis
- CT head if clinically indicated
- Endoanal ultrasound (EAUS) or MRI
 - evaluate tumour depth and sphincter/perirectal lymph node involvement
- HIV testing for those at higher risk



Your poll will show here

1



Install the app from
pollev.com/app

2

Make sure you are in
Slide Show mode

Still not working? Get help at pollev.com/app/help
or

[Open poll in your web browser](#)



TNM staging for anal cancer

Primary tumor (T)			
TX	Primary tumor cannot be assessed		
T0	No evidence of primary tumor		
Tis	Carcinoma in situ (Bowen's disease, high-grade squamous intraepithelial lesion (HSIL), anal intraepithelial neoplasia II-III (AIN II-III))		
T1	Tumor 2 cm or less in greatest dimension		
T2	Tumor more than 2 cm but not more than 5 cm in greatest dimension		
T3	Tumor more than 5 cm in greatest dimension		
T4	Tumor of any size invades adjacent organ(s), eg, vagina, urethra, bladder*		
Regional lymph nodes (N)			
NX	Regional lymph nodes cannot be assessed		
N0	No regional lymph node metastasis		
N1	Metastasis in perirectal lymph node(s)		
N2	Metastasis in unilateral internal iliac and/or inguinal lymph node(s)		
N3	Metastasis in perirectal and inguinal lymph nodes and/or bilateral internal iliac and/or inguinal lymph nodes		
Distant metastasis (M)			
M0	No distant metastasis		
M1	Distant metastasis		
Anatomic stage/prognostic groups			
0	Tis	N0	M0
I	T1	N0	M0
II	T2	N0	M0
	T3	N0	M0
IIIA	T1	N1	M0
	T2	N1	M0
	T3	N1	M0
	T4	N0	M0
IIIB	T4	N1	M0
	Any T	N2	M0
	Any T	N3	M0
IV	Any T	Any N	M1

Note: cTNM is the clinical classification, pTNM is the pathologic classification.

* Direct invasion of the rectal wall, perirectal skin, subcutaneous tissue, or the sphincter muscle(s) is not classified as T4.

Used with the permission of the American Joint Committee on Cancer (AJCC), Chicago, Illinois. The original source for this material is the AJCC Cancer Staging Manual, Seventh Edition (2010) published by Springer New York, Inc.

Treatment

- Historically treated by abdominoperineal resection
- Now first-line is **Nigro Protocol** (combined chemoradiotherapy):
 - 5-fluorouracil (5-FU) – days 1-4 and 29-32
 - mitomycin C (MMC) – days 1 and 29
 - External beam radiation to the pelvis
- Equivalent rates overall survival and higher disease-free survival
- Lower rates of local failure, tumor recurrence, and need for colostomy



Your poll will show here

1

Install the app from
pollev.com/app

2

Make sure you are in
Slide Show mode

Still not working? Get help at pollev.com/app/help
or

[Open poll in your web browser](#)

Prognosis

- **Tumor diameter** and **nodal status** are main prognostic factors
- 5-year survival rates
 - Stage I – 70%
 - Stage II – 59%
 - Stage III – 41%
 - Stage IV – 19%
- 5-year colostomy-free survival rates of 70-86%

Treatment of Residual/Recurrent Disease

- ~20-30% will have persistent or recurrent disease following primary CRT
- APR for salvage therapy
 - 5-year local-regional control in up to 30-77%
 - Overall survival rates 24-69%
- Chemotherapy (5-FU or cisplatin) for extrapelvic metastasis following surgical salvage
 - anecdotal data with biologic agents and surgical resection
 - median survival 9 months

Surveillance

- Anoscopy and inguinal exam
 - q 3-6 months for 5 years
- CT chest/abdo/pelvis for 3-5 years

Adenocarcinoma of Anal Canal

- Rare, 3-9% of anal carcinoma
- Many of these tumors represent rectal cancer with downward spread
- Determination of the anatomic site of origin of can be problematic
 - mucosa of the transitional zone in upper canal
 - base of the anal glands
 - chronic anorectal fistula

Management

- Treatment parallels rectal cancer
 - Surgical resection (typically an APR)
 - Chemotherapy and RT given as preoperative or postoperative therapy to improve local and systemic control

Anal Margin Cancers (aka Perianal Cancers)

- Completely visible and fall within a 5 cm radius of the anal verge
- Similar symptoms to anal canal cancer
- Diagnosis delayed due to location and indistinct features
 - almost 1/3 misdiagnosed at first physician visit but no difference in survival

Investigations

- CT chest
- CT abdo/pelvis
 - to assess liver met (rare) and nodal disease

Staging

- Staging of anal margin cancers by AJCC criteria follows that of skin cancer elsewhere
- T1-3 are staged the same manner as SCC of the anal canal
- T4 signifies invasion of deep extradermal structures such as bone, nerve, striated muscle, or cartilage
- N0 and N1 refer to no regional or regional lymph node spread

Treatment

- Varies depending on size and depth of invasion
- T1 and early T2:
 - WLE with a 1-cm margin or radiation therapy
 - 5-year survival rates up to 88%
- Larger T2
 - Radiation to primary lesion and inguinal fields

Treatment

- T3 and T4:
 - Radiation to both inguinal and pelvic fields +/- chemotherapy (5-FU or mitomycin C or cisplatin)
- APR
 - for larger and less favorable lesions (T2-4 or N1)
 - those involving the sphincter muscles
 - patients with incontinence or multiple recurrences after local excision
 - salvage for persistent or recurrent disease after radiation



Your poll will show here

1

Install the app from
pollev.com/app

2

Make sure you are in
Slide Show mode

Still not working? Get help at pollev.com/app/help
or

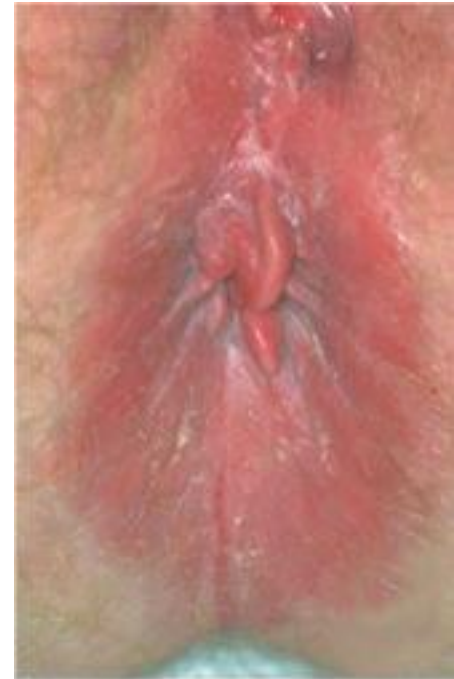[Open poll in your web browser](#)

Perianal Paget Disease

- Rare
- Intraepithelial adenocarcinoma
- Initially described in the breast
- Extramammary Paget disease can be found in the perianal area and other sites containing apocrine glands
- Origin of the neoplastic cells could be apocrine glands or epithelial stem cells

Clinical Presentation

- Occurs in the elderly
- Slowly spreading pruritic and erythematous rash
- Often mistaken as an eczema
 - Dx often delayed
 - 25% of patients with invasive disease have distant metastasis
- Synchronous visceral carcinomas found in up to 50%
 - identifying underlying primary is essential before any treatment
 - GI tract, skin, prostate, neck, nasopharynx



Treatment

- If non-invasive, locally confined disease
 - WLE with microscopically clear margin
- If associated with concomitant rectal adenocarcinoma:
 - follow rectal cancer protocols +/- inguinal lymph node dissection
- Recurrence rates up to 60%
 - treat with wide re-excision
- Other treatment modalities emerging

Anal Squamous Intraepithelial Lesions

- Other historical terms: squamous cell carcinoma in situ, anal intraepithelial neoplasia, Bowen's disease
- Precursor lesion to anal SCC
 - parallel observations in the cervix in which HPV causes development of cervical dysplasia
- Can be detected using anal Pap smear
- Classification:
 - LSIL – low-grade squamous intraepithelial lesion
 - HSIL – high-grade squamous intraepithelial lesion



Your poll will show here

1



Install the app from
pollev.com/app

2

Make sure you are in
Slide Show mode

Still not working? Get help at pollev.com/app/help
or

[Open poll in your web browser](#)



SIL and HIV

- Limited data for HIV-neg/immunocompetent patients
 - rare, slow growing
 - fewer than 10% progress to cancer
- LSIL
 - progresses to HSIL in >50% of HIV-pos homosexual males within 2 years
- HSIL
 - risk for progression to cancer 10-50%

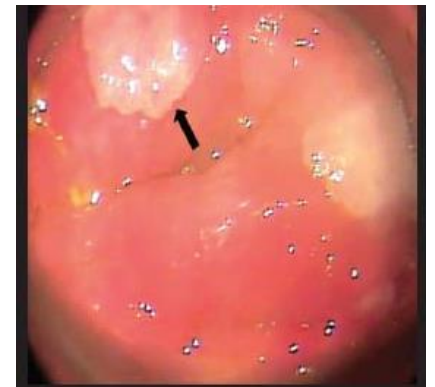Treatment

- Controversial
- “watch and wait” vs treatment

Expectant management with surveillance q4-6 months	
PRO	CON
<ul style="list-style-type: none">• high risk of recurrence following treatment• morbidity associated with repeated excision• low rates of disease progression and malignant potential (especially for LSIL)	<ul style="list-style-type: none">• clearance of HSIL in up to 80% and progression to invasive cancer in less than 5% with treatment

Treatment

- WLE with 1 cm margin guided by frozen section
 - recurrence rate 13-63%, high rates of local wound complications such as stenosis and incontinence
- Targeted therapy with high-resolution anoscopy (HRA)
 - recurrence rate 57%
- Others – anecdotal success
 - Topical imiquimod
 - immune response modifier with both anti-HPV and antitumor effects
 - Topical 5-fluorouracil
 - Laser therapy, radiotherapy, photodynamic therapy



Surveillance

- Close long-term follow up
- Surveillance examinations q3-6 months as long as dysplasia is present
 - Anal Pap smear
 - Anoscopy
 - High resolution anoscopy

Questions?